Chest MRI Symposium: More than meets the eye_see through lymphatics by MR imaging

SY21-1

Operation-related lymphatic injury and surgical management

Hong Kwan Kim

Department of Thoracic and Cardiovascular Surgery, Samsung Medical Center, Sungkyunkwan University School of Medicine, Seoul, Korea

1. What is chylothorax and when does it occurs?

Chylothorax is a potentially devastating complication of thoracic surgical procedures. Although surgical injury can involve all levels, including abdominal wounds after node dissection, thoracic wounds after lung, esophageal, mediastinal or aortic surgery, and cervical wounds after extensive neck dissection, esophageal surgery is probably the most common iatrogenic cause of chylothorax with the incidence reported from 0.2 to 10.5% of operations. Most injuries to the thoracic duct occur near the aortic and azygos arches where the relations between the esophagus and the thoracic duct are the closest.

2. What does chylothorax result in?

Chylothorax has local, immunological, and nutritional consequences, which can be serious and sometimes fatal. Locally, chylothorax can have an impact on the cardiorespiratory system via mechanical compression of the heart, potentially leading to tamponade. Similarly, respiratory distress can arise due to the development of pleural effusion, provoking progressive pulmonary atelectasis. After the acute phase, complications attributable to chylothorax are related to chronic depletion of chyle and are thus more common in patients given prolonged conservative treatment. Immunodepression can arise due to the fall in cellular and humoral immunity, which is itself secondary to lymphocyte and immunoglobulin depletion. Patients can thus become more vulnerable to infections, particularly in the postoperative period. Short-term electrolyte depletion leads to hypovolemia, metabolic acidosis, hyponatremia, hypocalcemia, and deficiencies in fat-soluble vitamins. Long-term loss of fatty acids and proteins can lead to a state of severe malnutrition. These complications explain the very high mortality of up to 30 to 50% among patients with untreated chronic chylothorax.

3. How can we manage patients with chylothorax?

Optimal management remains controversial. Some authors advocate conservative management while others propose early surgery. Conservative management aims to reduce chyle production through nutritional measures and control symptoms by draining the chylous effusion from the chest cavity. The end point for conservative management is spontaneous closure of the lymphatic vessels. Surgical intervention aims to identify and directly close the site of the leak.

Most authors agree that surgery should be reserved for failure of medical treatment. The question of how long to wait for the success of the medical treatment is still an open debate. Some authors recommend surgery early, only a few days after diagnosis in order to limit the morbidity and mortality associated with the operation. Others recommend waiting longer, about 2 weeks.

Elective ligation of the thoracic duct above the diaphragm has been proposed during esophagectomy to reduce the risk of chylothorax. This strategy does not however always prevent the complication (injury due to ligation, anatomical variant). Thus some authors propose ligating all lymphatic tissues situated between the mediastinal pleura, the spine, and the aorta. The ligature can pass approximately 2 cm above the transdiaphragmatic passage in order to leave a stump for potential surgical revision. Even with such measures, it appears that a zero rate of chylothorax cannot be achieved.

Chest MRI Symposium: More than meets the eye_see through lymphatics by MR imaging

SY21-2

Overview of lymphatic imaging

Ho Yun Lee

Radiology, Samsung Medical Center, Sungkyunkwan University School of Medicine, Seoul, Korea

Impairments of lymphatic circulation could occur from various causes, including congenital defect, secondary damage due to trauma or neoplasm. However, accurate assessment of the lymphatic system has been limited due to the lack of optimal diagnostic methods. Traditionally, the lymphatic system has been imaged by injecting contrast material or radiotracers into the feet or hands. This is not sufficient for assessment of the central conducting lymphatics (such as the thoracic duct or the cisterna chyli).

The recently developed intranodal lymphangiography and MR lymphangiography provide new insight into lymphatic pathology. Particularly, MR lymphangiography using heavily T2-weighted sequence appears to be a useful noninvasive technique in evaluation of lymphatic flow abnormalities involving the central lymphatic system including thoracic duct. Also it does not only depict better anatomical and functional lymphatic abnormality, but also identifies additional information other than lymphatic abnormalities based on its inherent advantage, including its higher spatial, temporal resolution, and ability of providing 3D images.

This overview will discuss the anatomy and function of the lymphatic system, the evolution of imaging of the lymphatic system, and noninvasive MR lymphangiography technique.

Keywords : Lymphatic disorders, Lymphangiography, Embolization, MR lymphangiography

Chest MRI Symposium: More than meets the eye_see through lymphatics by MR imaging

SY21-3

Noninvasive & invasive MR lymphangiography

So Hyeon Bak

Department of Radiology, Kangwon National University Hospital, Chuncheon, Korea

The lymphatic system plays an important role in maintenance of fluid balance, immune regulation, and transport of metabolites. Visualizing the lymphatic system is clinically necessary for diagnosis or treatment of many diseases. However, imaging of the lymphatic system is difficult due to the extreme complexity of lymphatic anatomy. This lack of imaging the lymphatic system for clinical application has limited the treatment options for patients with lymphatic flow disorders. Recently, noninvasive or invasive technologies for visualizing the lymphatic system have been applied for clinical applications. These techniques have led to the development of new treatment for patients with lymphatic flow disorders. We discuss the use of lymphatic imaging in experimental systems as well as some of the emerging noninvasive or invasive technologies.

Keywords : Lymphatic system, Imaging

Chest MRI Symposium: More than meets the eye_see through lymphatics by MR imaging

SY21-4

SNUH experience: Role of CT/MR Lymphangiography in Non-traumatic Lymphatic Leakage

Saebeom Hur

Radiology, Seoul National University Hospital, Seoul, Korea

The purpose of this study is to evaluate the usefulness and feasibility of dynamic contrast enhanced magnetic resonance lymphangiography (DCMRL) in the evaluation of various lymphatic leakages.

From October 2013 to February 2018, 18 sessions of DCMRL were performed in 10 patients among 115 patients who were referred to interventional radiology service of Seoul National University Hospital for the management of various lymphatic leakages [traumatic etiology (n=98) vs. non-traumatic etiology (n=17)].

They were allocated to 2 groups according to the location of the lymphatic leakage above or below the diaphragm: (1) Group A: chylous pleural or pericardial effusion (N=4), (2) Group B: chylous ascites, hepatic lymph ascites or protein losing enteropathy (N=4).

DCMRL could locate the probable leakage or effusive anatomic structures 100% (4/4) in Group A. Among total of 14 sessions of DCMRL in group A, 3 sessions were performed prior to thoracic duct embolization (TDE) while the other 11 were to evaluate the presence of collateral route when the chylous leakage persisted after the thoracic duct embolization. All sessions DCMRL provided additional information on the status of lymphatic system in relation with the chylous leakage.

On the contrary, only one out of 6 patients (17%) in Group B showed positive findings explaining the symptom. DCMRL performed in all other 5 patients showed only normal retroperitoneal lymphatic system and thoracic duct. Even in the only case with positive findings, those findings may not explain all the leakages but there is a high chance of additional lesions in the mesenteric lymphatic system, which could not be seen by this examination modality. This clear limitation of DCMRL in the evaluation of chylous leakage below the diaphragm is believed to be closely related to the flow direction of hepatic lymph and mesenteric chylous lymph that are not mixed with the contrast agent injected via the inguinal lymph node before they adjoin at the cisterna chyli (Figure 1).

In conclusion, DCMRL can provide useful information on the chylous leakage from the lesions above the diaphragm but has clear limitation in the evaluation of the lesions below the diaphragm. Further research and development of new technology are needed to improve the usefulness of DCMRL in chylous leakage below the diaphragm.

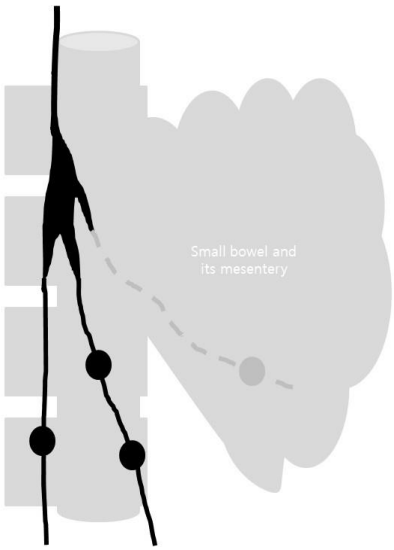

Fig.1. The flow direction of hepatic lymph and mesenteric chylous lymph that are not mixed with the contrast agent injected via the inguinal lymph node before they adjoin at the cisterna chyli

Keywords : Intervention, Chylothorax, Lymphangiography, Lymphatic

Chest MRI Symposium: More than meets the eye_see through lymphatics by MR imaging

SY21-5

SMC experience: focus on noninvasive MRL

Dongho Hyun

Department of Radiology, Samsung Medical Center, Seoul, Korea

Lymphatic leakage from the thoracic duct, if untreated, can lead to high morbidity and mortality in early postoperative period. When the amount is over 20ml/kg/day or 1000ml/day, by the text, either thoracic duct ligation or mass ligation is performed with open thoracotomy or in an either thoracoscopic or laparoscopic approach. Recently, percutaneous thoracic duct embolization has been gaining popularity since favorable clinical outcome with low complication rate since a study was published in 2010. On the one hand, lights have also been shedding on imaging tools to depict the lymphatic system as the number and needs of lymphatic intervention increase. Between lymphatic imaging modalities, magnetic resonance (MR) imaging is one of the extensively investigated fields.

Thanks to heavily T2 weighted sequence MR lymphangiography (MRL) delineates the central thoracic or abdominal lymphatic system with no contrast agent which is prerequisite for all the other radiologic examinations including even dynamic contrast-enhanced MR lymphangiography. Non-invasive MRL can be readily performed because of no need for intranodal or subcutaneous contrast injection and specialized facility such as angiography suite combined with MR machine. Given that postoperative chylothorax is largely caused by damage to the main thoracic duct or its main tributaries, non-invasive MRL is one of the optimal imaging solutions to this circumstance.

The current lecture reports our experiences on the role of non-invasive MRL and lymphatic intervention in the management of postoperative chylothorax following lung and esophageal cancer at a single tertiary referral center.

Keywords : Lymphatic imaging, MRI, Lymphangiography

Chest MRI Symposium: More than meets the eye_see through lymphatics by MR imaging

SY21-6

AMC Experience: Focus on Invasive MR Lymphangiography

Ji Hoon Shin

Department of Radiology, Asan Medical Center, Seoul, Korea

Introduction

Methods of imaging the lymphatic system have lagged behind vascular imaging, primarily due to difficulty in delivering contrast material into the lymphatic vessels. Pedal lymphangiography, which is technically challenging and time-consuming, was replaced with intranodal lymphangiography, which is based on ultrasound-guided access of inguinal lymph nodes.

Application of a similar intranodal contrast delivery technique for MR imaging resulted in the development of the dynamic contrast MR lymphangiography (DCMRL). MR acquisition technique to track the advancement of contrast material, allows dynamic imaging of the flow in the lymphatic systems as well as imaging of the lymphatic masses and vessels.

Imaging technique of dynamic contrast MR lymphangiography

XMR suite (Siemens, Germany) that combines an MR scanner with a cardiac catheterization laboratory is available, enabling both imaging and intervention together; however, it is not available in Korea. Therefore, it is practical to separate intranodal puncture procedure and MR acquisition.

Heavy T2W imaging

This imaging is similar to MRCP and exceptionally sensitive for detection of fluid-filled lymphatic structures. Bone lymphatic masses, lymphangiectasis and possibly thoracic duct can be identified sensitively. Heavy T2W imaging can be performed using a respiratory-navigated and cardiac-gated 3D turbo spin echo sequence.

Dynamic contrast MR lymphangiography

Weight-based dose of undiluted MR contrast material is injected by hand simultaneously into each inguinal lymph node at a rate of 1 mL/min. Two types of imaging are performed: dynamic over the period of 10 to 15 minutes and delayed, high-resolution at the end of the study.

Advantages of DCMRL

1) Generation of the map / pathway of the lymphatic flow – reflux, leakage
2) Less artifacts from breathing, peristalsis, or heart move
3) Better visualization of smaller lymphatic ducts
4) Possible visualization of delayed lymphatic flow in complex lymphatic flow (e.g. slow lipiodol flow)
5) Avoidance of unnecessary conventional lymphangiography when DCMRL is normal for selected cases (e.g. suspicious leakage cases)

Disadvantages of DCMRL

1) Technical difficulty in intranodal contrast injection - contrast extravasation by capsular rupture or cannula slippage
2) Non-visualization of lymphatic structures outside injected contrast material pathway - cannot evaluate extremity, mesenteric, or intraperitoneal

References

1. Dori Y, Zviman MM, Itkin M. Dynamic contrast-enhanced MR lymphangiography: feasibility study in swine. Radiology 2014;273:410–416.
2. Krishnamurthy R, Hernandez A, Kavuk S, et al. Imaging the central conducting lymphatics: initial experience with dynamic MR lymphangiography Radiology 2015;274:871–878

3. Itkin M. Magnetic Resonance Lymphangiography and Lymphatic Embolization in the Treatment of Pulmonary Complication of Lymphatic Malformation. Semin Intervent Radiol 2017 Sep;34(3):294-300